

CONTEMPORARY OB/GYN[®]

Translating science into sound clinical practice

EXPERT EXCHANGE How to Formulate the Relationship Between the Ob/Gyn and the Interventional Radiologist for the Treatment of Uterine Fibroids



Peggy K. Onstad
GENERAL MANAGER AND
GROUP PUBLISHER

Kathleen Hiltz
NATIONAL SALES MANAGER

Carlos Cornejo
NATIONAL SALES MANAGER

Samantha Armstrong
NATIONAL SALES MANAGER

John C. Marlow, MD
CHIEF MEDICAL AND
COMPLIANCE OFFICER



Joseph Loggia
CHIEF EXECUTIVE OFFICER

Ted Alpert
EXECUTIVE VICE
PRESIDENT—FINANCE,
CHIEF FINANCIAL OFFICER

Georgiann DeCenzo
Chris DeMoulin
R. Steve Morris
Daniel M. Phillips
EXECUTIVE VICE PRESIDENTS

Eric I. Lisman
EXECUTIVE VICE PRESIDENT—
CORPORATE DEVELOPMENT

Mike Alic
VICE PRESIDENT—
ELECTRONIC MEDIA

Shelbie O'Brien
VICE PRESIDENT
AND CONTROLLER

Francis Heid
VICE PRESIDENT—
MEDIA OPERATIONS

Rick Treese
VICE PRESIDENT AND
CHIEF TECHNOLOGY OFFICER

Ward D. Hewins
VICE PRESIDENT—
GENERAL COUNSEL

Nancy Nugent
VICE PRESIDENT—
HUMAN RESOURCES

The views and opinions expressed are those of the participants and do not necessarily reflect those of Advanstar Communications Inc, publisher of *Contemporary OB/GYN*.

PARTICIPANTS

John H. Fischer II, MD
Assistant Professor of Radiology
St. Luke's Episcopal Hospital
Baylor College of Medicine
Houston, Texas

Robert K. Zurawin, MD
*Associate Professor of Obstetrics
and Gynecology*
Baylor College of Medicine
Houston, Texas

Benign uterine fibroids are the most common types of tumor in a woman's pelvis. According to the American College of Obstetricians and Gynecologists (ACOG), these fibroids occur in approximately 25% to 50% of all women, with the highest incidence reported in women aged 30 to 40 years.¹ Most fibroids are so small and asymptomatic that women are unaware of their presence. Even large fibroids may not cause bothersome symptoms, although they commonly are found in women who have menorrhagia (heavy periods), frequent urination, pelvic pain, back pain, infertility, and/or pregnancy loss (Table 1).^{1,2}

Table 1. Effects of Uterine Fibroids^{1,2}

- Changes in menstruation (excessive bleeding, longer and/or more frequent menses, menstrual cramps)
- Anemia as a consequence of blood loss
- Abdominal or lower back pain; rectal pain; dyspareunia
- Pressure from enlarged uterus causing difficulty urinating, constipation
- Infertility; miscarriage

These symptoms can lead a physician to suspect uterine fibroids, but frequently a patient with fibroids is asymptomatic and the tumors initially are detected first during routine pelvic examination. Several diagnostic tools, including ultrasonography, sonohysterography, magnetic resonance imaging (MRI), hysteroscopy, and laparoscopy, may be used to evaluate tumors and determine their size, morphology, and location. Although ultrasonography has the lowest sensitivity and specificity for diagnostic purposes, it is usually the first test conducted because it is widely available, noninvasive, and cost-efficient. Although it is more costly and time consuming than ultrasonography, MRI offers better tissue characterization and has the ability to detect adenomyosis, which may cause symptoms identical to fibroids. Sonohysterography and diagnostic hysteroscopy are effective in detecting submucous fibroids in the patient with excessive menstruation.

Knowledge of the full range of treatment options enables physicians to counsel patients on the optimal management of uterine fibroid tumors and to provide the best possible care for their patients. For this issue, *Contemporary OB/GYN* invited 2 specialists—John H. Fischer II, MD, of the Department of Radiology at St. Luke's Episcopal Hospital and of Baylor College of Medicine in Houston, Texas, and Robert K. Zurawin, MD, of the Department of Obstetrics and Gynecology at Baylor College of Medicine—to discuss their approaches to patient management and how their practice relationship has led to a winning combination of successful patient outcomes and innovative cooperation between the ob/gyn and interventional radiologist for a comprehensive offering of treatments for fibroids.

Contemporary OB/GYN: The number of treatment options for uterine fibroids has increased. Although hysterectomy is the definitive treatment of symptomatic fibroids, the choice of treatment depends on many factors. How do you describe the options?

Dr. Fischer: We can divide the choices into traditional surgical options such as open hysterectomy and open myomectomy, and minimally invasive surgical procedures such as laparoscopic hysterectomy, laparoscopic myomectomy, and hysteroscopic myomectomy. In addition, hormonal and pharmacologic choices are available. Image-guided options include uterine fibroid embolization (UFE) and, more recently, MRI-guided focused ultrasound (MRgFUS) (Table 2).²

Table 2. Treatment Options for Women With Uterine Fibroid Tumors (Listed From Least Invasive to Most Invasive)²

Treatment	Description	Advantages	Disadvantages
Hormonal agents	Symptomatic relief; reduces bleeding; decreases tumor size	No procedure necessary; may be used as temporizing measure or adjunctive therapy to other treatments	Long-term treatment; consequences of menopausal-like symptoms and bone loss; high recurrence rate; fertility preservation may be dependent on subsequent procedures; temporary therapy, as symptoms recur when treatment ends
MRgFUS	Ultrasound waves penetrate anterior abdominal wall and heat fibroid tissue, causing cell death at focal points identified by MRI	Outpatient procedure; no surgical incision; no anesthesia necessary; short recovery time with minimal discomfort	Procedure requires 4 hours on average; not intended for large or numerous fibroids; currently limited data and limited third-party reimbursement
UFE	Nonsurgical, interventional radiologic procedure to nearly occlude uterine arteries (blood supply to fibroids)	No surgical incision; no anesthesia necessary; favorable recovery time; few major complications	Postembolization syndrome (pain, fever, leukocytosis) is common; fibroids/symptoms may recur, necessitating additional procedures
Endometrial ablation	Hysteroscopic destruction of the endometrium to reduce menorrhagia	Can effectively control menorrhagia despite presence of fibroids	May not be technically feasible in some patients with myomas in uterine cavity; will not reduce bulk symptoms
Myomectomy	Open surgical or endoscopic excision of tumors	Symptom resolution with fertility preserved; minimal procedural blood loss (if done via laparoscopy)	Perioperative morbidity similar to hysterectomy; prolonged recovery (after open surgery); recurrence of tumors, persistent vaginal bleeding; success can be limited by number and extent of tumors
Hysterectomy	Surgical removal of uterus (may be transabdominal, transvaginal, or laparoscopic)	Definitive treatment	Loss of fertility; prolonged recovery (after open surgery); surgical risks dependent on type of procedure

Dr. Zurawin: Women are becoming increasingly aware of the existence of options for treating uterine fibroids that avoid open abdominal surgery. At best, major abdominal surgery is an unpleasant option, but for some women it is totally unacceptable. Added to the fact that many women want to avoid surgery altogether, they also want to retain their uterus at all cost, no matter how big, painful, or problematic it may be. Women's perception of the options available is really a driving force. They may have unrealistic expectations about uterine preservation or potential for future fertility. The role of the gynecologist is to be familiar with all options and help guide each particular patient toward the best treatment plan for her.

Dr. Fischer: There is no perfect fibroid treatment, and no one treatment option is best for every patient. It becomes a multifactorial decision that takes into account the patient's symptoms, medical history, and size, number, and location of her fibroids. Often patients may qualify for more than one treatment option. This is when patient choice becomes important. For the most part, though, few cases are alike.

Contemporary OB/GYN: UFE is a nonsurgical approach to the treatment of uterine fibroids. The procedure is usually performed with local anesthesia and intravenous sedation. A microcatheter is introduced through the femoral artery and is guided fluoroscopically into the uterine artery. Small particulate embolic agents are injected and used to nearly occlude the uterine arteries—the blood supply to the fibroids. The procedure was first reported in 1995, and the Fibroid Registry for Outcomes Data for Uterine Embolization was formed in 1999 to collect prospective data on more than 2000 women who had undergone embolization for

fibroid tumors.³ A recent report from the Fibroid Registry found that UFE results in durable improvement in quality of life.³ What features of fibroids make patients good candidates for UFE?

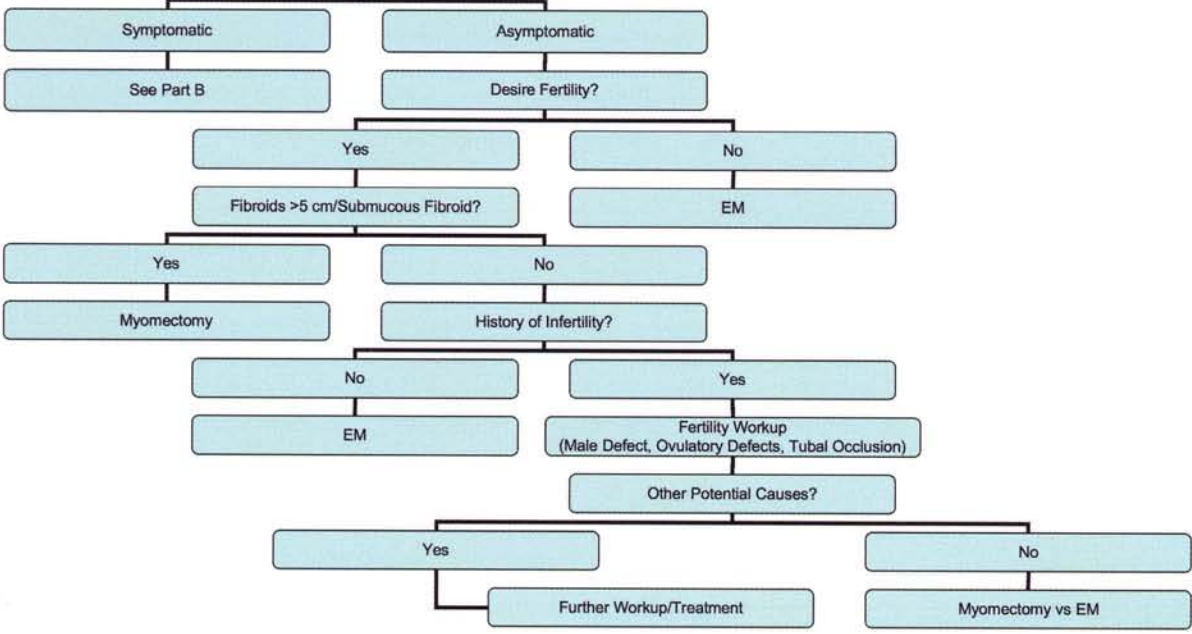
Dr. Fischer: The size, number, and location of the fibroids are very important in determining whether a patient is an appropriate candidate for UFE. There are, however, many other factors that also must be considered. We have developed a treatment algorithm that can help both interventional radiologists and gynecologists determine the best treatment option for a particular patient (Figure, page 4).

Dr. Zurawin: Although hysterectomy can be performed in a minimally invasive manner and cures the problem, UFE has many advantages over hysterectomy. The issue of preservation of fertility is a concern for many women. Most studies have shown that myomectomy, the surgical removal of the fibroid, is better than UFE with regard to fertility, although some evidence points favorably toward UFE in women who have fibroids of certain numbers and sizes, and in certain locations.

Dr. Fischer: I agree. Furthermore, in some cases, such as in women who have innumerable fibroids scattered throughout the uterus, myomectomy may not be a viable option because all the fibroids may not be removable or the surgery may be technically challenging and pose increased risk. This is especially true in patients who have had one or more previous pelvic surgeries, like myomectomy.⁴ These women may be good UFE candidates, and in this particular subset of patients, we would consider doing UFE, despite the patient's desire to maintain fertility.

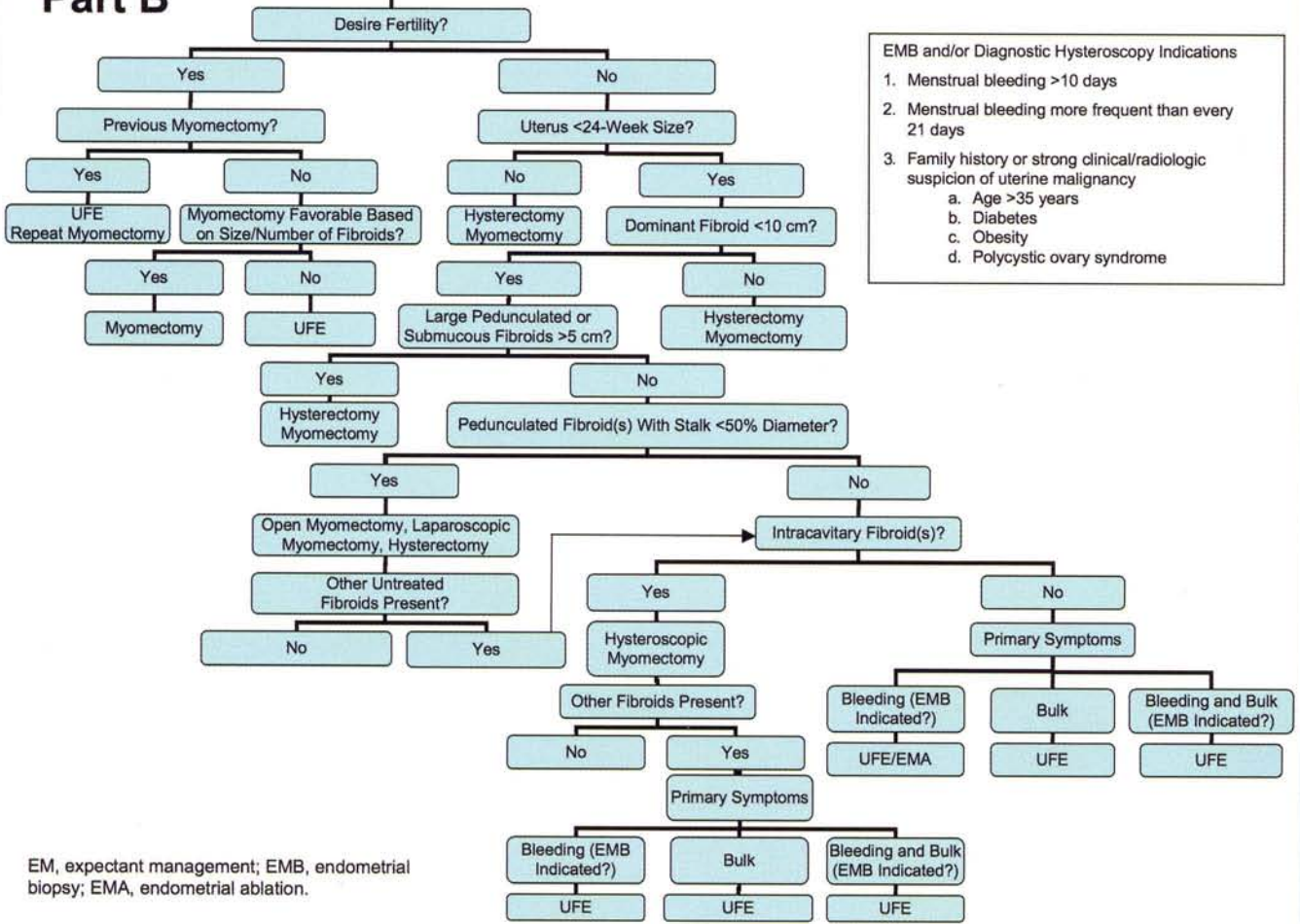
Part A

FIBROIDS



Part B

Symptomatic



- EMB and/or Diagnostic Hysteroscopy Indications
1. Menstrual bleeding >10 days
 2. Menstrual bleeding more frequent than every 21 days
 3. Family history or strong clinical/radiologic suspicion of uterine malignancy
 - a. Age >35 years
 - b. Diabetes
 - c. Obesity
 - d. Polycystic ovary syndrome

EM, expectant management; EMB, endometrial biopsy; EMA, endometrial ablation.

Contemporary OB/GYN: A review of existing literature in 2004 showed that until further data are available, laparoscopic myomectomy, open myomectomy, and hysteroscopic resection are preferred procedures in patients desiring future fertility.⁵ Research since that time has looked at specific outcomes of pregnancies following UFE and myomectomy. A retrospective analysis of pregnancies after UFE performed by the same interventional radiologist identified 56 completed pregnancies that occurred among approximately 1200 women after UFE.⁶ In this study, approximately 31% of the women who were attempting to become pregnant actually did. Another study found that almost twice as many women became pregnant after myomectomy compared with UFE (33 vs 17), although the difference between the groups was less evident in abortion rate (6 vs 9).⁷ Although the question of fertility after UFE remains one for further study, pregnancy is possible after UFE and may be preferable to myomectomy in selected cases.

What about the imaging techniques used to guide UFE? Do you prefer to use ultrasonography or MRI of the uterus when you consider UFE?

Dr. Fischer: In my opinion, every patient considering UFE should have an MRI unless she has a contraindication, like a pacemaker or incompatible medical implant or metallic foreign body. MRI provides the same information as ultrasonography but has advantages over ultrasonography in terms of providing information about tissue characterization and evaluating the blood supply to the fibroids. In addition, although no imaging study can diagnose malignancy, MRI is a fairly reliable tool for the diagnosis of adenomyosis. Ultrasonography cannot do that. If an MRI is not performed, evaluation of the patient as a candidate for UFE will be limited, and the risk of treatment failure may be increased.

Dr. Zurawin: We are on the frontier of the most advanced, comprehensive, and successful treatment available for women with uterine fibroids. Women today have options ranging from completely noninvasive procedures such as MRgFUS to minimally invasive techniques like UFE, laparoscopic or hysteroscopic surgery, all the way to traditional open abdominal surgery. The ability to offer all those choices is based on effective consultation between radiologist and gynecologist; by incorporating available evidence and experience, Dr. Fischer and I have developed an approach we feel ultimately will lead to optimal patient care.

Contemporary OB/GYN: The trend of women taking a proactive role in the course of their health care is increasingly evident. A survey that examined the information-seeking behavior of women who required treatment of symptomatic uterine fibroids found that they were more interested in learning about the treatments available, their benefits, and their risks than they were about learning the reasons their physician recommended a particular course of action.⁸

Dr. Fischer: This trend is driven by patient preference for less invasive procedures and shorter recovery times. Women are seeking minimally invasive surgical and image-guided treatment options. They cannot be away from work or their normal activities

for the 4 to 6 weeks of recovery time that is associated with traditional surgery. These patients are often well informed and have researched various fibroid treatment options prior to their initial consultation.

Dr. Zurawin: Typically, once a woman has received the diagnosis of fibroids, she seeks information. Whether it is from the Internet or her aunt, girlfriend, or cousin, women are becoming aware of alternatives.

Contemporary OB/GYN: How do ob/gyns perceive UFE?

Dr. Fischer: In my experience, there is a wide spectrum. Some gynecologists have no interest in participating in the care of UFE patients, nor are they willing to offer it as an option. Others discuss UFE as a treatment option with patients they perceive as viable candidates. Most gynecologists fall somewhere in between these extremes. In my opinion, as more procedures are performed and more data become available, the role of UFE will be clearer and the gynecologic community will be more likely to offer the procedure as an option to properly selected patients.

Dr. Zurawin: Many gynecologists lack an appreciation of the features and potential of UFE and perceive it as a radiological alternative that is threatening their own patient base. Ob/Gyns should be aware of their patients' preferences just as they are in other situations, such as with patients who request birth plans. Gynecologists may not be particularly sensitive to a patient's intensely personal feelings about the effect of fibroids on her future. Equally important, the gynecologist may lack the skills necessary to offer minimally invasive alternatives like laparoscopic or hysteroscopic myomectomy and consequently guides the patient toward the open procedures that he or she is more comfortable performing.

Furthermore, many appropriate referrals are missed simply because the gynecologist is not knowledgeable about UFE.

Dr. Fischer: One aspect of UFE that is particularly misunderstood is the postembolization syndrome, which includes postprocedure pain, fever, malaise, and leukocytosis and occurs to some degree after every embolization procedure. This should not be considered a complication of the procedure, as it is an expected result. (The HOPEFUL [Hysterectomy or Percutaneous Embolisation for Uterine Leiomyomata] study did not include postembolization syndrome as a complication, but rather a general side effect.) Patients experience similar symptoms after embolization of liver and kidney tumors. Therefore, interventional radiologists are very familiar with this syndrome and know that it is self-limiting, usually lasting about a week. Patients may require symptomatic treatment, and pain control is usually the most important issue. It is vital to educate not only the patient, but also the patient's gynecologist and all other physicians caring for the patient to avoid misdiagnosis of infection and an unnecessary workup.

In my opinion, perceptions of gynecologists about UFE and other less invasive fibroid treatment options have widened in the past 5 years. Today, many gynecologists feel less threatened by these procedures and recognize them as viable and important options for many patients.

Contemporary OB/GYN: Please describe the role of the interventional radiologist in providing gynecologic care.

Dr. Fischer: I advocate a collaborative approach. The interventional radiologist must be an integral part of the team, and in some cases the leader of the team, because he or she best understands the UFE procedure. The most important part of developing a successful UFE practice is for the interventional radiologist to take primary responsibility for the clinical care of the patients. The interventional radiologist has to accept the primary role of handling routine postprocedure care and any complications that may arise after UFE. The interventional radiologist also must be willing to communicate with the patient and the patient's gynecologist and/or other referring physician. This responsibility includes initial patient workup, patient education, expectation management, and postprocedure care. This is looked upon very favorably by most gynecologists and other members of the patient's health care team. We tell every patient that if she has any questions she thinks may be even remotely related to UFE—not just in the weeks following the procedure, but even several months after—she should call the interventional radiologist first. We involve the gynecologist or other attending physician only if she requires surgery or other management beyond the scope of our practice.

Dr. Zurawin: I agree with Dr. Fischer. It has been our experience that a team approach allows for optimal patient care. It is not dependent on who sees the patient first; it depends on the patient's experience and what serves her best. We frequently see patients who have combined problems—they may need both embolization and laparoscopic or hysteroscopic removal of fibroids. For example, a patient may have large fibroids causing bulk symptoms in addition to a pedunculated submucous fibroid causing menorrhagia. A hysteroscopic myomectomy to eliminate the source of heavy bleeding may be done first, allowing optimal success of the UFE. The team approach illustrated by our algorithm is successful when both the interventional radiologist and the gynecologist are comfortable with offering a wide variety of procedures.

The relationship that I have with Dr. Fischer has allowed both of us to see many more patients than if we were not working with each other. By combining our resources and our expertise, we have a unique relationship that enables us to evaluate, treat, and help all women with fibroids, regardless of how they present. This approach is very attractive to patients, and it supports our working together. A patient may need the radiologic procedure more than a surgical one; another may need the surgical procedure more. As far as we are concerned, we are busier and more productive as a result of our collaboration. And at the end of the day, the patients receive better care.

Dr. Fischer: Offering as many options as possible to a patient makes the patient feel as if she received the best care possible. The goal should not be to do as many UFEs, hysterectomies, or minimally invasive surgeries as possible. The goal should always be to do what is best for the patient. Within that context, if the patient has a preference, it is likely that allowing for that preference will result in the most satisfied patients and a very successful practice. It is important to listen to the patient and allow her input into the treatment and the decision-making process. This type of patient care translates into more referrals and more respect from patients and other physicians.

Dr. Zurawin: I agree entirely. The practice can benefit when patients seek out the team approach. I am gratified to be in the position of teaching fellows and residents to do the right thing for patients and I am motivated to increase use of a procedure that is helping to accomplish that.

Contemporary OB/GYN: What are the primary obstacles to forming a successful relationship between the interventional radiologist and the gynecologist?

Dr. Zurawin: There are many obstacles (Table 3). From the gynecologist's point of view, the loss of control of the patient may be a major concern, coupled with a perception of loss of revenue or concerns that the radiologist will not handle postoperative complications. In addition, a physician may have a lack of comfort or experience with his or her ability to perform the minimally invasive procedures that are sometimes necessary and adjunctive to managing patients treated with UFE.

Dr. Fischer: I can understand why gynecologists are reluctant to recommend UFE. If they refer patients to an interventional radiologist, many fear they will have to manage the postoperative care and potential complications of UFE. This is the reason that it is so important for interventional radiologists to accept primary responsibility for the care of their patients. For the interventional radiologist, the perception that they can perform the UFE procedure and expect the gynecologist to manage the patient before and after the procedure can quickly destroy even the most successful practice.

Dr. Zurawin: That is why the team approach is the best, one in which both the gynecologist and the radiologist are involved and the patient understands the short-term and long-term effects of the procedure. This is especially important in complex cases in which multiple factors influence the outcomes. For example, a woman has had a UFE and returns in a few months with a prolapsed cervical fibroid that degenerated as a result of the successful UFE, but is causing discharge. While this is a natural outcome of UFE in some patients, the prolapse will be treated by the gynecologist.

We frequently see patients who have combined problems. A woman may need both embolization and fibroid removal, either laparoscopically or hysteroscopically; one procedure may not be sufficient. Many gynecologists are not trained to offer multiple

minimally invasive options—laparoscopic hysterectomy, laparoscopic myomectomy, hysteroscopic myomectomy, endometrial ablation procedures—which dovetail with UFE. It may be that a woman is not a suitable candidate for the UFE procedure or another minimally invasive gynecologic procedure, but the referring physician is not experienced in performing any minimally invasive procedures. Let's take the example of a woman who knows she has fibroids and who doesn't want a hysterectomy and goes directly to the interventional radiologist, who performs an MRI and finds a pedunculated myoma on a slender stalk. UFE is not optimal in this case and the radiologist advises the woman to go to her gynecologist to have it removed. If the gynecologist is not capable of performing a laparoscopic myomectomy and instead offers only open myomectomy or, even worse, total abdominal hysterectomy, the patient is stymied.

Dr. Fischer: The largest hurdle for the interventional radiologist is the provision of primary clinical care for the UFE patients, a concept that I have already stressed several times. The interventional radiologist must be willing and able to step up and provide primary clinical care. This may include answering the pager at all hours of the day or night and being willing to admit, round on, manage, and discharge these patients. Unfortunately, this level of commitment is foreign to most radiologists, but is essential for developing a successful UFE program.

The primary obstacles for most gynecologists is the poor understanding of the potential benefits and limitations of UFE and other less invasive treatment options such as hysteroscopic and laparoscopic myomectomy and laparoscopic hysterectomy. Gynecologists also must realize that by working in collaboration with a dedicated interventional radiologist to offer all the available treatment options, listening to their patients, and allowing the patient to participate in the decision-making process, their practices will be significantly enhanced. Becoming familiar with and offering less invasive surgical options, if possible, is also important.

Table 3. Barriers to Achieving an Optimal Relationship Between Ob/Gyn and Interventional Radiologist

- Ob/Gyn lack of confidence in and knowledge of UFE
- Ob/Gyn lack of experience with minimally invasive procedures
- Ob/Gyn perceptions concerning interventional radiologist's expertise in managing patients' postprocedure symptoms
- Perception of shortage of experienced interventional radiologists in geographic area
- Ob/Gyn fear of loss of revenue or financial disincentives in referring patients to interventional radiologist
- Interventional radiologist unwillingness to provide primary clinical management of the UFE patients

Contemporary OB/GYN: What can be done to overcome some of these barriers?

Dr. Fischer: There are many ways to overcome the barriers (Table 4). Communication and education, with both patient and physician, is vital so that the patient and gynecologist know what to expect. The interventional radiologist must make a clinical commitment and then reach out to the local gynecologic community.

Dr. Zurawin: Gynecologists need to become familiar with the indications and advantages of UFE and seek out an interventional radiologist with whom a team approach can be established. I would especially like to see more encouragement and support directed toward educating residents in minimally invasive surgery. One of the reasons why radiologists are performing many of these procedures is that gynecologists may not have the necessary technical expertise to offer acceptable alternatives. Shared expertise can enhance the potential for the radiology and gynecology practices to work more closely together and to form a team approach to patient care.

Dr. Fischer: I would like to add that while any fellowship-trained interventional radiologist should be capable of performing embolization, there is a learning curve with any procedure and experience is important. If an interventional radiologist performs chemo embolization of renal and liver tumors only, he or she may feel less comfortable with performing UFE, especially in complicated cases. The techniques, however, are similar, whether it is a chemo embolization, an embolization of a gastrointestinal bleed, or a UFE.

Table 4. Steps Toward Achieving an Optimal Relationship Between Ob/Gyn and Interventional Radiologist

- Interventional radiologist to assume primary care responsibility for patients
- Ob/Gyn to offer *all* treatment options to *all* patients with fibroids
- Interventional radiologist to handle all patient care and communication with referring ob/gyn
- Ob/Gyn to be educated on UFE and its benefits and limitations
- Interventional radiologist's practice to have nurse practitioner or physician assistant to support clinical care
- Interventional radiologist to receive the support of his/her practice
- Interventional radiologist and ob/gyn to collaborate on patient criteria for various therapies

Contemporary OB/GYN: What are the strategies for developing successful relationships between ob/gyns and interventional radiologists?

Dr. Zurawin: Doing what is best for the patient is a winning strategy. When you refer a patient, you are almost assured of getting 10 referrals back. And that is true from both sides. As shown in our algorithm, we now have enough outcomes data to formulate the best approach to care for women with uterine fibroids who fit within a given set of parameters.

Dr. Fischer: I agree with Dr. Zurawin that ultimately doing what is best for the patient is always the best approach. The ideal situation is for the patient to be under concurrent care of both the gynecologist and the interventional radiologist. This is truly a win-win situation.

Contemporary OB/GYN: The 2 of you obviously have developed a strong relationship. How did you accomplish it?

Dr. Fischer: It was evident very early on that we shared similar philosophies and that each of us could benefit from a team approach to providing minimally invasive surgical procedures

and UFE. More importantly, both of us are willing to think outside the box. In the end, the patients benefit the most.

Dr. Zurawin: Our relationship formed as a natural progression of my involvement in the minimally invasive surgery program at Baylor College of Medicine. Once we started working together, we realized that we share the same philosophy of patient care and that our practices fit well together. It is essential that Dr. Fischer's practice encompasses primary care and maintains personnel that can handle patient care prior to, during, and after the procedure.

Dr. Fischer: In some ways Dr. Zurawin and I are at opposite ends of the spectrum, but we have been able to successfully combine newer image-guided procedures and minimally invasive surgical options. Our goal is to offer every available treatment option to women with fibroids—not just myomectomy/hysterectomy—within one institution.

Contemporary OB/GYN: You have explained the key points involved in developing a relationship between ob/gyns and interventional radiologists to facilitate and increase the adoption of UFE as a treatment option for women with uterine fibroids. To summarize, what guidance would you give ob/gyns and interventional radiologists about UFE?

Dr. Fischer: I would suggest that both gynecologists and radiologists discuss all available treatment options with their patients who have uterine fibroids. From an interventional radiologist's perspective, I can state that UFE, like all procedures, is not for everybody. In many patients, however, UFE and less invasive surgical options can be effective treatment alternatives to traditional surgery. As always, favorable outcomes are most dependent on patient selection. The collaborative efforts of gynecologists and radiologists in treating fibroids best serve the patients.

Dr. Zurawin: I recommend Dr. Fischer's approach, which may be different from other radiologists who are offering UFE. His practice provides complete care for the patient. He will examine the patient, perform the procedure, and handle postoperative care, and he has a team of professionals who will support him. This is essential to making the process successful.

Dr. Fischer: Given that the clinical approach to a successful UFE practice is very different from that of the traditional practice of radiology, it also is very important for the interventional radiologist to have the support of his or her radiology group. This support will ensure the necessary infrastructure to provide a high level of clinical service, including personnel and office staff to schedule appointments, maintain patient charts, coordinate patients, and manage patient insurance issues. Adding a mid-level practitioner, such as a nurse practitioner or physician assistant, also may be necessary to leverage the physician's time, make the practice run most efficiently, and provide a higher level of clinical care. We added a nurse practitioner to our program approximately one year ago. This was a major and unfamiliar step for our group, but it has provided the necessary level and continuity of care.

Dr. Zurawin: Our system works well because we are able to offer the full range of options to the patient within an ethical context of providing what we think is the best treatment plan based on her individual situation.

Contemporary OB/GYN: UFE is a safe and highly effective treatment for women with symptomatic uterine fibroids. As more outcomes data become available, the technique will become more appreciated as a mainstream treatment option. Ob/Gyns who forge successful relationships with interventional radiologists optimize the quality of care offered to women with fibroids and provide benefit to both practices.

References

1. American College of Obstetricians and Gynecologists. Uterine fibroids. http://www.acog.org/publications/patient_education/bp074.cfm. Accessed February 8, 2008.
2. Evans P, Brunsell S. Uterine fibroid tumors: diagnosis and treatment. *Am Fam Physician*. 2007;75(10):1503-1508.
3. Goodwin SC, Spies JB, Worthington-Kirsch R, et al; Fibroid Registry for Outcomes Data (FIBROID) Registry Steering Committee and Core Site Investigators. Uterine artery embolization for treatment of leiomyomata. *Am J Obstet Gynecol*. 2008;111(11):22-33.
4. Yoo EH, Lee PI, Huh CY, et al. Predictors of leiomyoma recurrence after laparoscopic myomectomy. *J Minim Invasive Gynecol*. 2007;14(6):690-697.
5. Olive DL, Lindheim SR, Pritts EA. Non-surgical management of leiomyoma: impact on fertility. *Curr Opin Obstet Gynecol*. 2004;16(3):239-243.
6. Walker WJ, McDowell SJ. Pregnancy after uterine artery embolization for leiomyomata: a series of 56 completed pregnancies. *Am J Obstet Gynecol*. 2006;195(5):1266-1271.
7. Mara M, Maskova J, Fucikova Z, Kuzel D, Belsan T, Sosna O. Midterm clinical and first reproductive results of a randomized controlled trial comparing uterine fibroid embolization and myomectomy. *Cardiovasc Intervent Radiol*. 2008;31(1):73-85.
8. Ankem K. Information-seeking behavior of women in their path to an innovative alternate treatment for symptomatic uterine fibroids. *J Med Libr Assoc*. 2007;95(2):164-175.